

Reduced Radiotherapy Volumes for Cervical Cancer in a Second Trimester Gravid Patient: A Case Report



Patricia Ong, MD,¹ Mark Dumago, MD,¹
 Carl Jay Jainar, MD¹, Vannesza Hendricke Chua, MD,¹
 Kelvin Ken Yu, MD,¹ Jocelyn Mariano, MD,^{2,3}
 Warren Bacorro, MD^{1,4}

ABSTRACT

Purpose: To report the technical details and outcomes of a case of cervical cancer in pregnancy treated with reduced standard radiation volume via Intensity Modulated Radiation Therapy (IMRT).

Methods: A 33-year-old G4P3 (3003) was diagnosed with cervical squamous cell carcinoma at 17 weeks of gestation. She had a 5-year

history of intermittent post-coital bleeding and an incidental finding of a cervical mass during prenatal ultrasound. Internal examination revealed a 6-cm mass with no extension to the upper vagina and pliable bilateral parametria, leading to a staging of IB3. A multidisciplinary meeting with a gynecologic oncologist, radiation oncologist, medical ethicist and the patient was held wherein different treatment options were discussed. She consented to definitive external beam radiation therapy (EBRT) with concurrent cisplatin and was administered during 19-25 weeks of gestation using IMRT. A prescribed dose of 45 Gy in 25 fractions was delivered to the entire cervix with a 1-cm geometric expansion covering the lower uterus, and upper vagina as well as the pelvic lymph nodes, followed by four fractions of brachytherapy.

Results: The patient tolerated treatment with only grade 1 gastrointestinal and genitourinary adverse effects. After completion of concurrent chemoradiation, she underwent induction of labor and delivered a nonviable fetus. Three months post-treatment, MRI found no evidence of disease. At 15 months follow-up, she remains asymptomatic with no palpable disease.

Conclusion: This report demonstrates that treating only the involved uterus may be considered in cases wherein giving the full radiation dose to the whole uterus may lead to significant toxicities and eventual treatment interruption.

✉ Patricia J. Ong, MD
 patriciaong1231@gmail.com

- ¹ Department of Radiation Oncology, Benavides Cancer Institute, University of Santo Tomas Hospital, España Boulevard, Sampaloc, Manila, 1015 Metro Manila, Philippines
- ² Department of Obstetrics and Gynecology, University of Santo Tomas Hospital, España Boulevard, Sampaloc, Manila, 1015 Metro Manila, Philippines
- ³ Department of Obstetrics and Gynecology, University of Santo Tomas - Faculty of Medicine and Surgery, España Boulevard, Sampaloc, Manila, 1015 Metro Manila, Philippines
- ⁴ Department of Clinical Epidemiology, University of Santo Tomas - Faculty of Medicine and Surgery, España Boulevard, Sampaloc, Manila, 1015 Metro Manila, Philippines

Academic editor: Leilani B. Mercado-Asis

Submitted date: August 4, 2025

Accepted date: September 11, 2025

INTRODUCTION

Cervical cancer remains one of the top causes of cancer-related morbidity and mortality among women. About 66% of cervical cancer is diagnosed during the reproductive age.[1] In the Philippines, it is the second most common cancer diagnosed between the ages 15-45 years.[2] It is rare to diagnose cervical cancer during pregnancy up to 1 year postpartum. However, a significant increase in the incidence of cervical dysplasia diagnosed during pregnancy has been noted over the past years due to late child bearing.[3] Although there is international consensus with the availability of comprehensive protocols for gynecologic cancers diagnosed during pregnancy, standardized treatment may not always be possible.[4] Hence, treatment during pregnancy needs to be individualized taking into account the stage of disease, gestational age, obstetric complications and patient's decision regarding the pregnancy.

This report aims to present a case of stage IB3 cervical cancer during the second trimester, treated with reduced radiotherapy volume, highlighting its feasibility and favorable outcome.

CASE DETAILS

This is a case of a 33-year-old female G4P3 (3003), at 15 weeks age of gestation (AOG), who came into our institution's tumor clinics due to biopsy-proven well-differentiated squamous cell carcinoma of the cervix. On her first prenatal checkup two months prior, an obstetric ultrasound was done, revealing an early intrauterine pregnancy at 7 weeks by crown rump length. Incidentally, a heterogenous mass measuring 1.50 x 2.42 x 2.38 cm was also noted in the anterior lip of the cervix with abnormal vascularity that was suspicious of malignancy. She recalled having a history of intermittent postcoital vaginal bleeding for the past five years, but otherwise had no other gynecologic complaints. No Papanicolaou smear was done previously. After the prenatal ultrasound, she underwent cervical punch biopsy which revealed a well-differentiated squamous cell carcinoma. She was advised to see a gynecologic oncologist for further evaluation and management.

During her first gynecology-oncology consultation in our tumor clinics, at 15 weeks AOG, a speculum

exam showed a fungating, friable cervical mass that easily bled upon contact. On internal examination, the friable mass was approximately 6 cm in size with no extension to the proximal vagina. Fornices were deep. The uterus was enlarged to a size consistent with her then gestational age of 15 weeks. On the rectovaginal exam, the parametria were free and pliable bilaterally. Apart from bleeding after the internal examination, the patient had no other symptoms relating to the cervical mass.

A multidisciplinary meeting involving gynecology oncology, radiation oncology and medical ethicists was immediately held to assess treatment options. Two approaches were considered viable: (1) the first option was to administer neoadjuvant chemotherapy followed by definitive chemoradiation after delivery of the fetus, while (2) the second option was to proceed with definitive chemoradiation, with the risk of fetal demise. However, clinicians involved preferred the second option as the cervical mass seemed to rapidly enlarge between the period of the first prenatal check-up and first gynecology oncologic consult. Considering significant risk to the patient without timely treatment, the positive outcome of preserving her life outweighs the unintended harm, making the decision ethically defensible. Both options, including their advantages and risks, were thoroughly discussed with the patient. The patient and her partner were given ample time to decide between themselves.

After careful consideration, the patient chose to undergo definitive chemoradiation followed by high dose rate (HDR) intracavitary brachytherapy, consenting to the high risk of fetal demise. The clinicians discussed the possible decrease in local control provided by the treatment regimen as there may be a delay with brachytherapy taking into consideration recovery time needed after child birth. Prior to definitive management, the patient underwent full metastases work-up with a chest x-ray and a whole abdominal computerized tomography (CT) scan with contrast which were negative for visceral metastases and para-aortic lymph node metastases. Informed consent was obtained from the patient prior to receiving definitive radiation therapy with concurrent chemotherapy. She received a total of 45 Gy in 25 daily fractions of external beam radiotherapy (EBRT) concurrently with five cycles of Cisplatin followed by four sessions of brachytherapy at 19 to 25 weeks AOG.

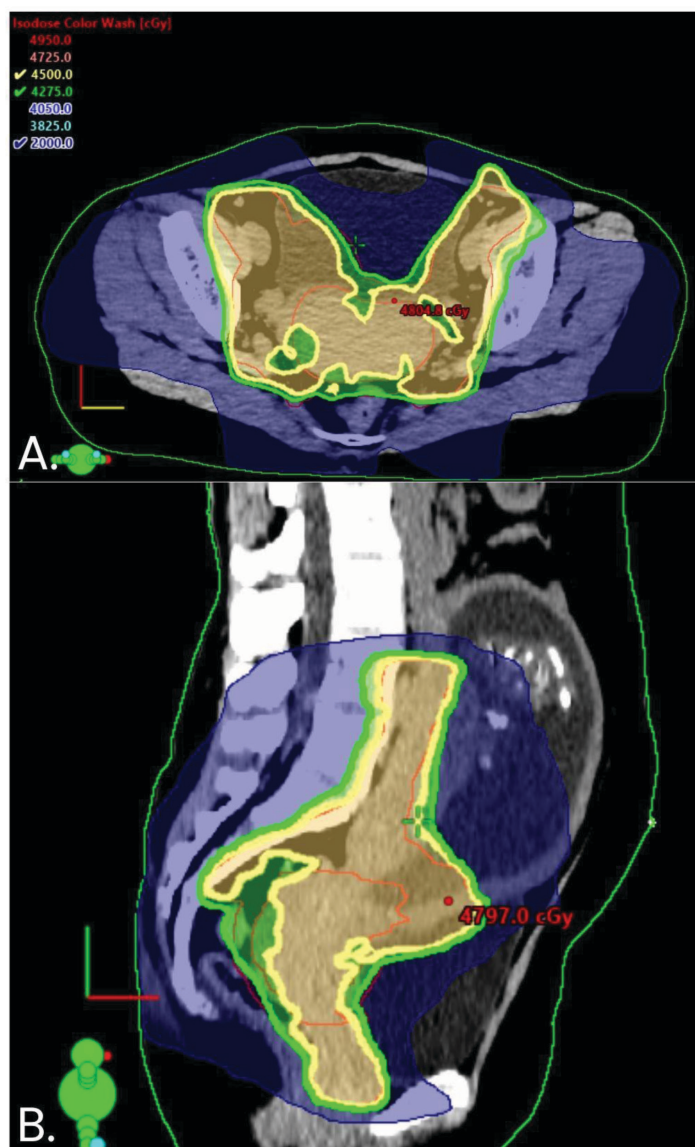


Figure 1: Treatment dose showing 100% and 95% of prescribed dose in A) Transverse view and B) Sagittal view

Table 1: Cumulative dose and constraints

Target/ Organ	Max Dose (cGy)	Mean Dose (cGy)	D95%	D100%	OAR constraints
PTV_4500	4841	4589	4445	3620	
GTVp	4809	4585	4460	4342	
Upper Uterus	4803	2509	ccc	ccc	
Bowel Bag	3267	685	103	72	D0.03cc (Gy) ≤53.5 V45.0Gy (cc) ≤ 195
Rectum	4682	3608	962	475	D0.03cc (Gy) ≤52.00 D50% (Gy) ≤ 45
Bladder	4820	3298	1352	1353	D0.03cc (Gy) ≤52.00 D50% (Gy) ≤ 45

OAR = organ at risk, PTV = planning target volume, GTVp = gross tumor volume (primary)

MATERIALS AND METHODS

The patient was immobilized using a customized vacuum cushion with a knee wedge. A CT simulation scan in supine position was done with 2.5 mm slice thickness. The clinical target volumes

(CTVs) were defined as follows: CTV1 includes the whole cervix with a 10-mm isogeometric expansion covering the lower uterus, CTV2 includes bilateral parametria and proximal one-third of the vagina, and CTV3 includes the elective pelvic lymph

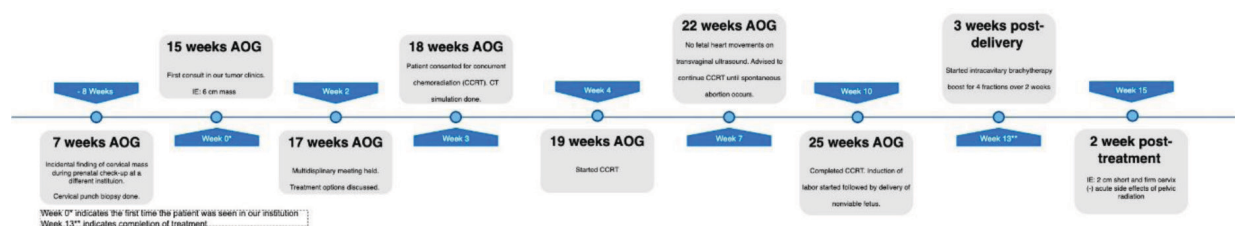


Figure 2: Treatment course of the patient

nodes, starting superiorly from the common iliac, external iliac, internal iliac, presacral and ending inferiorly to the obturator lymph nodes. The planning target volumes (PTVs) were created by expanding the CTVs as follows: PTV1 and PTV2 = CTV1 and CTV2 + 8 mm, while PTV3 = CTV3 + 5 mm, smaller margins were assumed due to the gravid uterus resulting in less room for internal motion. The three PTVs were combined to form one volume, PTV_4500.

A total of 4500 cGy was prescribed to the PTV_4500 to be delivered via IMRT techniques at 180 cGy per daily fraction. The goal was for 95% of the PTV_4500 to receive 100% of the prescribed dose, but with priority given to the organs at risk.

Image guidance using cone beam CT (CBCT) was done during the first fraction and at week 5 of EBRT. Thereafter, orthogonal kV-MV portal images bone matching was done weekly.

This report was approved by the University of Santo Tomas Hospital-Research Ethics Committee (USTH-REC). It was conducted in accordance with the applicable International Conference on Harmonization (ICH) Guidelines on Good Clinical Practice (GCP), National Ethical Guidelines for Health and Health-Related Research 2017 (NEGHR 2017).

RESULTS

The patient tolerated treatment with only grade 1 gastrointestinal and genitourinary adverse effects. Fetal movement was regularly monitored and noted to be present until the third week of chemoradiation. A transvaginal ultrasound was done 24 hours after no fetal movements were noted which showed fetal demise. On internal examination, the cervix was closed, hence gynecologic oncologists advised to continue chemoradiation until spontaneous abortion. If treatment was completed without delivery, either labor induction or cesarean delivery were both possible options. The patient completed 25 days

of EBRT at 25 weeks AOG after which the patient underwent induction of labor and subsequently delivered a nonviable fetus. Three weeks after, she underwent four fractions of intracavitary brachytherapy at 650 cGy per fraction. The patient completed all treatment procedures over 11 weeks.

Follow-up internal examination two weeks post-treatment revealed a short and firm cervix, approximately 2 cm in diameter. The uterus and bilateral adnexa are unremarkable. The patient had resolution of acute gastrointestinal and genitourinary side effects. The patient was then followed up monthly for the first three months under the service of gynecology-oncology. Three months post-treatment, pelvic MRI showed no distinct enhancing mass lesion in the cervix with no enlarged pelvic lymph nodes. Four months post-treatment, Papanicolaou smear was negative for malignant cells. The patient was then scheduled for followup every four months with repeat monitoring via Papanicolaou smear. Serial Papanicolaou smear was all negative for malignant cells.

On the latest follow-up, 15 months post-treatment, the patient is asymptomatic with no late toxicities such as vaginal dryness and stenosis, dyspareunia, proctitis, incontinence, or fistula. On internal examination, the cervix was short and firm, approximately 1 cm in diameter, otherwise unremarkable.

DISCUSSION

Amongst the rare combination of gynecologic cancer and pregnancy, studies have shown that cervical cancer has the highest incidence.[5] In the third and latest international consensus conducted by the International Network on Cancer, Infertility and Pregnancy (INCIP), pregnant patients with locally advanced cervical cancer (stage IB3 and above) are preferably treated with definitive chemoradiation resulting in the termination of pregnancy.[4] However, for those wishing to preserve pregnancy, neoadjuvant chemotherapy may be administered at

14 weeks AOG, followed by radical surgery after cesarean delivery. Neoadjuvant chemotherapy may be omitted for those diagnosed at 22 weeks AOG or later with treatment of definitive chemoradiation delayed and given after cesarean delivery.[4]

For those receiving definitive chemoradiation during pregnancy, the next challenge would be to determine our treatment volume. The French recommendations would advise that chemoradiation therapy should be delivered according to the standards of cervical cancer in a nonpregnant patient.[4] This includes giving the same radiation doses, radiation therapy fields, as well as concomitant chemotherapy. The fetus is ideally evacuated prior to delivering radiation. However, if this is not possible, then treatment will be given with the fetus in utero.

Based on the latest European Society of Gynecological Oncology (ESGO) jointly with the European Society for Radiotherapy and Oncology (ESTRO) and the European Society of Pathology (ESP) guidelines, the standard clinical treatment volume for early cervical cancer includes the primary tumor, whole cervix, whole parametria, whole uterus, upper vagina, as well as lymph node drainage which includes the obturator, internal, external and common iliac and presacral region.[6] The planning goal for EBRT is to receive 45 Gy in 25 fractions.

On the CT simulation scan, the fundus of the uterus was at the level of L1-L2. Following the standard protocol, more than half of the abdomen will receive radiation (Figure 1). Amongst the gynecologic malignancies, whole abdominal irradiation is sparingly used in ovarian cancers as adjuvant or salvage treatment due to its toxicity.[7,8] A dose of 36 Gy delivered to the whole abdomen via conventional radiotherapy techniques using anteroposterior/posteroanterior fields with maximal organ at risk (OAR) shielding results in chronic grade 3-4 gastrointestinal, hematologic and renal adverse effects. In addition, there is a significant increased risk of bowel obstruction independent of other risk factors.[9] Newer studies have used IMRT and volumetric modulated arc therapy (VMAT) to increase sparing of OAR.[10] However, most would not prescribe higher than 30 Gy in 1.5 Gy per fraction to the whole abdomen with no additional boost given to the pelvis given the potential toxicities.[11,12]

The standard guidelines would dictate that the whole gravid uterus needs to be irradiated at 45 Gy in 2 Gy per fraction.[6] If standard volumes were

to be treated in the patient, there was potential risk of the patient not tolerating treatment due to toxicity leading to treatment interruption. Moreover, studies have found that a delay in treatment completion with an overall treatment time longer than 8 weeks result in poorer progression-free survival and overall survival.[13]

Due to the high possibility of increased toxicity, the whole gravid uterus was not included in the radiated volume for the patient. Instead, only the involved uterus was treated to 45 Gy. A phase II prospective study investigating locally advanced cervical cancer in South Korea also treated with partial volumes including only the involved uterus, although their study population did not include pregnant patients. In this study, only the involved uterus was treated to 50 Gy. At 30 months, the progression-free survival was at 82.78% with only 8.2% of locoregional recurrence.[14]

In this case report, the patient was able to complete 25 days of EBRT with concurrent cisplatin with no interruption due to severe toxicity. There was no evidence of disease based on MRI three months post-treatment. A limitation of this case was the three-week treatment break between completion of EBRT and initiation of brachytherapy resulting in an 11-week overall treatment time. This three-week break was due to childbirth and postpartum recuperation. Nevertheless, the outcome from reduced volume was promising as there was still no evidence of disease 15 months post-treatment.

CONCLUSION

We report a case of stage IB3 cervical cancer in the second trimester of pregnancy treated with non-standard partial radiation volume via IMRT. This case report shows that including only the involved uterus in the treatment volume was effective in treating cervical malignancies. This partial volume may be considered in cases wherein giving the full radiation dose to the whole uterus may lead to significant increase in toxicities and eventual treatment interruption.

CONFLICT OF INTEREST

The investigators do not have any commercial nor financial affiliations. This research will not receive any specific grant from funding agencies.

AUTHOR CONTRIBUTIONS

PO: Conceptualization, Investigation, Resources, Writing – Original Draft, Visualization, Project Administration

MD: Validation, Investigation, Resources, Writing – Original Draft

CJ: Validation, Investigation, Resources, Writing – Original Draft, Visualization

VC: Validation, Investigation, Resources, Writing – Original Draft, Visualization

KY: Validation, Investigation, Writing – Review and Editing, Supervision

JM: Conceptualization, Writing – Review and Editing, Supervision

WB: Conceptualization, Writing – Review and Editing, Supervision, Project Administration

Informed Consent

Written informed consent was obtained from the patient for publication of this case report and accompanying images.

REFERENCES

- Sung H, Ferlay J, Siegel RL, Laversanne M, Soerjomataram I, Jemal A, et al. Global cancer statistics 2020: GLOBOCAN estimates of incidence and mortality worldwide for 36 cancers in 185 countries. *CA Cancer J Clin* [Internet]. 2021;71(3):209–49. Available from: <https://doi.org/10.3322/caac.21660>
- Cervical cancer coverage: A top priority of PhilHealth in Universal Health Care [Internet]. Philippine Health Insurance Corporation. Manila: Department of Health; 2022 [cited 2025 Apr 1]. Available from: https://www.philhealth.gov.ph/news/2023/cervical_coverage.pdf
- Le Guévelou J, Selleret L, Laas E, Lecuru F, Kissel M. Cervical cancer associated with pregnancy: Current challenges and future strategies. *Cancers (Basel)* [Internet]. 2024;16(7):1341. Available from: <https://doi.org/10.3390/cancers16071341>
- Amant F, Berveiller P, Boere IA, Cardonick E, Fruscio R, Fumagalli M, et al. Gynecologic cancers in pregnancy: guidelines based on a third international consensus meeting. *Ann Oncol* [Internet]. 2019;30(10):1601–12. Available from: <https://doi.org/10.1093/annonc/mdz228>
- Morice P, Uzan C, Gouy S, Verschraegen C, Haie-Meder C. Gynaecological cancers in pregnancy. *Lancet* [Internet]. 2012;379(9815):558–69. Available from: [https://doi.org/10.1016/S0140-6736\(11\)60829-5](https://doi.org/10.1016/S0140-6736(11)60829-5)
- Cibula D, Raspollini MR, Planchamp F, Centeno C, Chargari C, Felix A, et al. ESGO/ESTRO/ESP Guidelines for the management of patients with cervical cancer - Update 2023. *Int J Gynecol Cancer* [Internet]. 2023;33(5):649–66. Available from: <https://doi.org/10.1136/ijgc-2023-004429>
- Dembo AJ, Bush RS, Beale FA, Bean HA, Pringle JF, Sturgeon J, et al. Ovarian carcinoma: improved survival following abdominopelvic irradiation in patients with a completed pelvic operation. *Am J Obstet Gynecol*. 1979;134(7):793–800.
- Smith JP. Postoperative treatment of early cancer of the ovary: A random trial between postoperative irradiation and chemotherapy. In: Symposium on Ovarian Carcinoma [held at Reston, Virginia, November 15 and 16, 1974]. Vol. 42. No. 42. Bethesda: US Department of Health, Education, and Welfare, Public Health Service, National Institutes of Health, National Cancer Institute; 1975.
- Firat S, Murray K, Erickson B. High-dose whole abdominal and pelvic irradiation for treatment of ovarian carcinoma: long-term toxicity and outcomes. *Int J Radiat Oncol Biol Phys* [Internet]. 2003;57(1):201–7. Available from: [https://doi.org/10.1016/s0360-3016\(03\)00510-8](https://doi.org/10.1016/s0360-3016(03)00510-8)
- Mahantshetty U, Jamema S, Engineer R, Deshpande D, Sarin R, Fogliata A, et al. Whole abdomen radiation therapy in ovarian cancers: a comparison between fixed beam and volumetric arc based intensity modulation. *Radiat Oncol* [Internet]. 2010;5(1). Available from: <https://doi.org/10.1186/1748-717x-5-106>
- Hong L, Alektiar K, Hunt M, Leibel S. Intensity modulated radiotherapy for soft tissue sarcoma of thigh. *Int J Radiat Oncol Biol Phys* [Internet]. 2002;54(2):139–40. Available from: [https://doi.org/10.1016/s0360-3016\(02\)03298-4](https://doi.org/10.1016/s0360-3016(02)03298-4)
- Rochet N, Sterzing F, Jensen A, Dinkel J, Herfarth K, Schubert K, et al. Helical tomotherapy as a new treatment technique for whole abdominal irradiation. *Strahlenther Onkol* [Internet]. 2008;184(3):145–9. Available from: <https://doi.org/10.1007/s00066-008-1772-z>
- Monk BJ, Tian C, Rose PG, Lanciano R. Which clinical/pathologic factors matter in the era of chemoradiation as treatment for locally advanced cervical carcinoma? Analysis of two Gynecologic Oncology Group (GOG) trials. *Gynecol Oncol* [Internet]. 2007;105(2):427–33. Available from: <https://doi.org/10.1016/j.ygyno.2006.12.027>
- Lee HC, Jeong JW, Lee JH, Kim SH, Park DC, Yoon JH, et al. High-dose (60 Gy) intensity-modulated radiotherapy with concurrent weekly cisplatin followed by intracavitary radiation in locally advanced cervical cancer: A phase II prospective clinical trial. *Gynecol Oncol* [Internet]. 2023;177:142–9. Available from: <https://doi.org/10.1016/j.ygyno.2023.08.018>



Open Access This article is licensed under a Creative Commons Attribution-NonCommercial-ShareAlike 4.0 International License, which permits use, share — copy and redistribute the material in any medium or format, adapt — remix, transform, and build upon the material, as long as you give appropriate credit, provide a link to the license, and indicate if changes were made. You may do so in any reasonable manner, but not in any way that suggests the licensor endorses you or your use. You may not use the material for commercial purposes. If you remix, transform, or build upon the material, you must distribute your contributions under the same license as the original. You may not apply legal terms or technological measures that legally restrict others from doing anything the license permits. The images or other third party material in this article are included in the article's Creative Commons license, unless indicated otherwise in a credit line to the material. If material is not included in the article's Creative Commons license and your intended use is not permitted by statutory regulation or exceeds the permitted use, you will need to obtain permission directly from the copyright holder. To view a copy of this license, visit <https://creativecommons.org/licenses/by-nc-sa/4.0/>.